

RECOARCTATIA DE AORTA

CAZ CLINIC

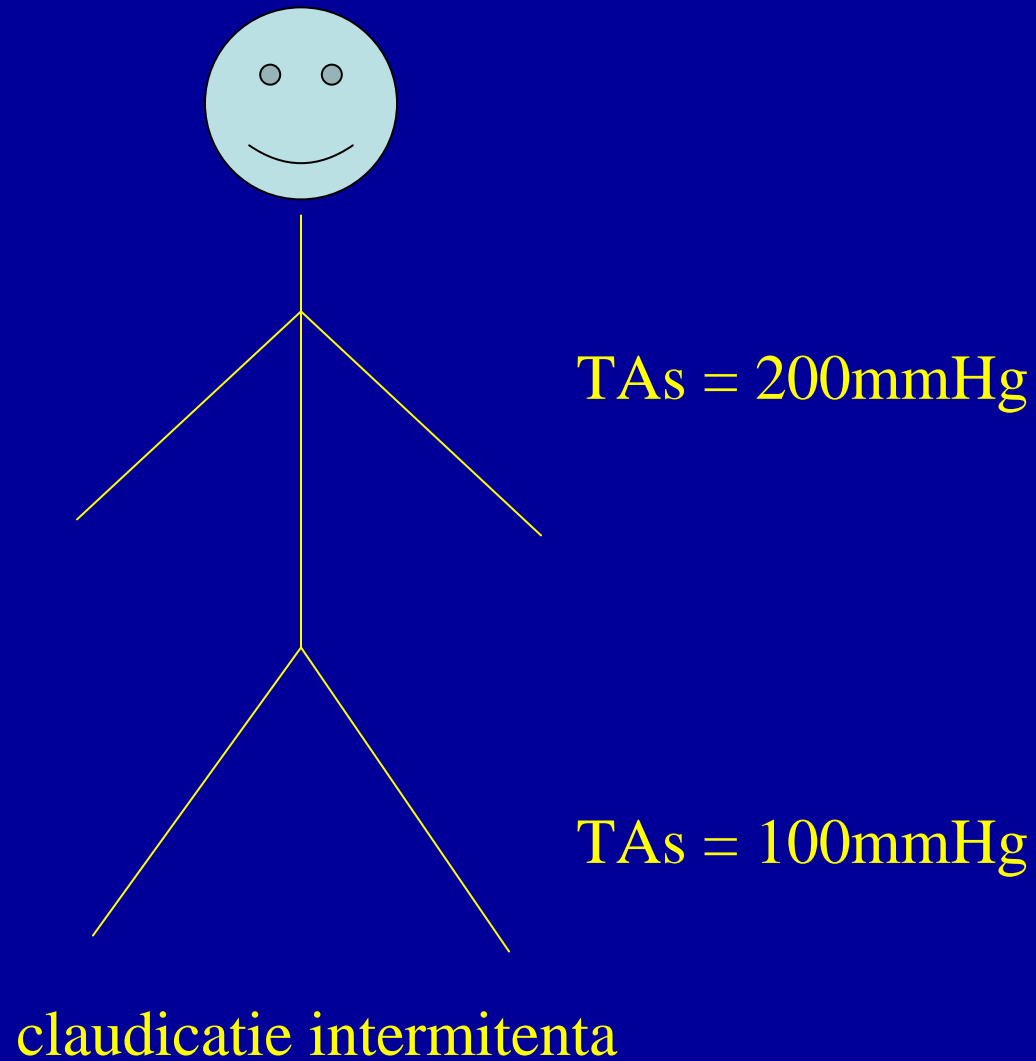
NADIA ANGHELACHE, MARINELA SERBAN, MARIAN ALBU

INSTITUTUL DE BOLI CARDIOVASCULARE “PROF. DR. C.C. ILIESCU “

INSTITUTUL CLINIC FUNDENI

- Pacientul C.I., in varsta de 36 de ani, din mediul urban
- AHC: nesemnificative
- APP: la varsta de 6 ani interventie chirurgicala pentru coarctatie de aorta

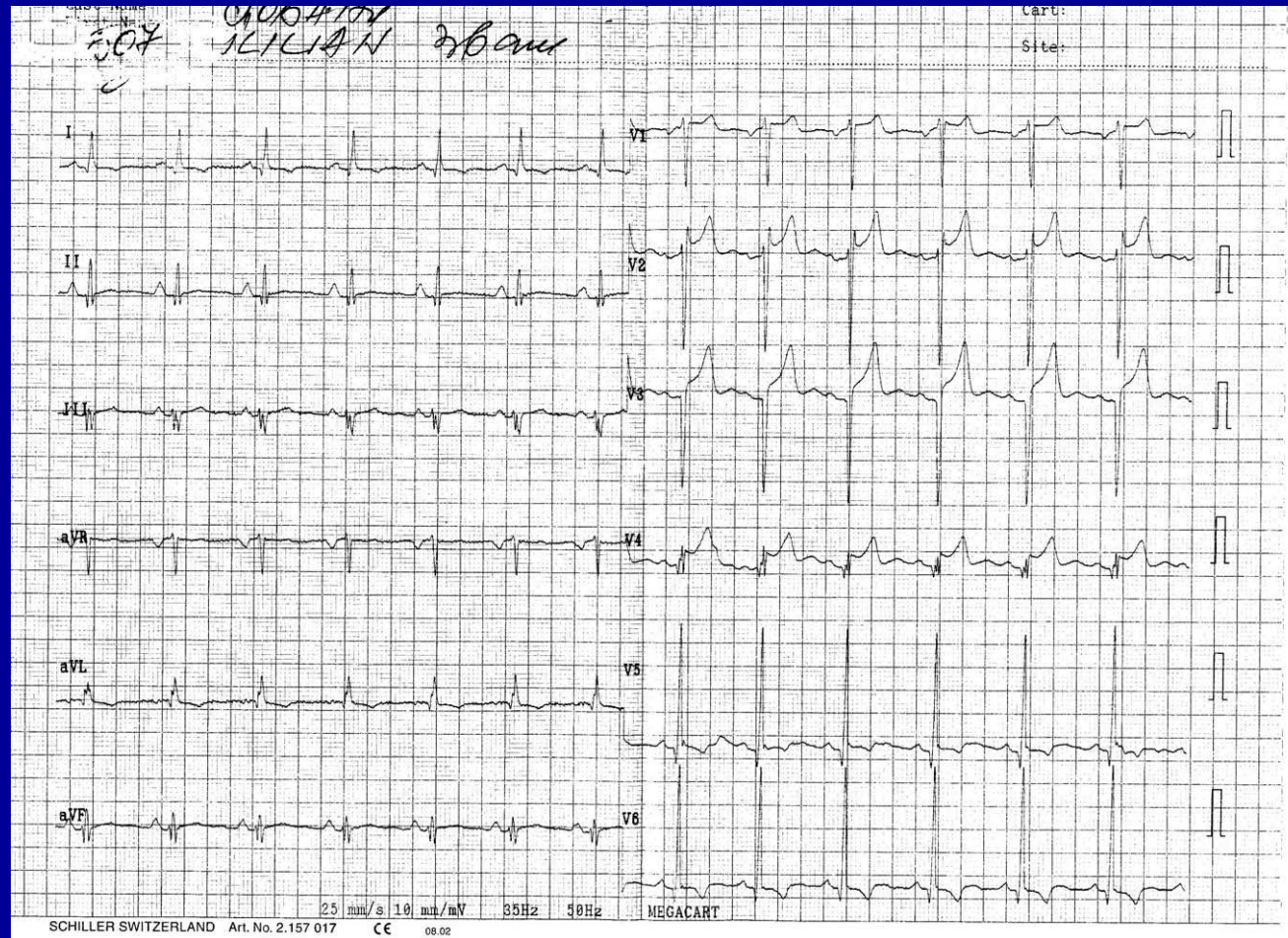
MOTIVELE INTERNARII



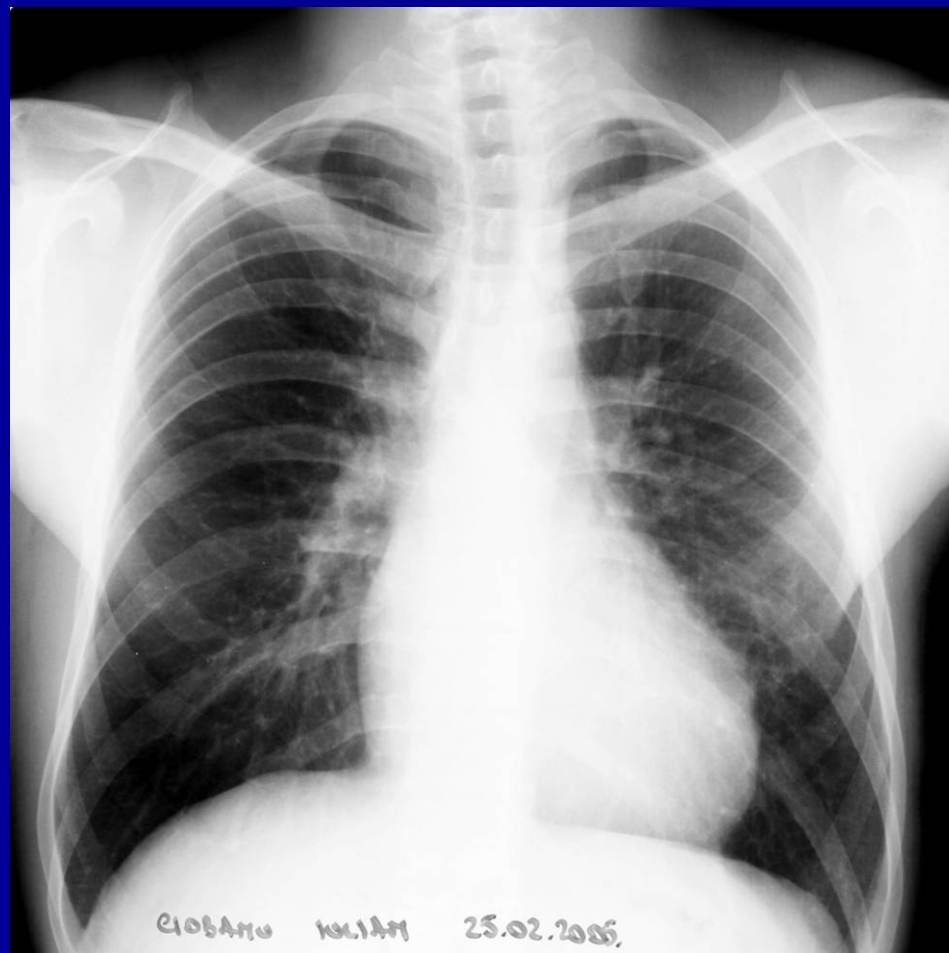EXAMENUL OBIECTIV

- TA brat drept=200/90 mmHg
- TA brat stang =190/90 mmHg
- TAs membre inferioare = 100 mmHg
- AV=96/minut regulat
- Suflu sistolic gradul IV/VI in spatiul IV intercostal stang parasternal , suflu sistolic gradul IV/VI interscapular
- Puls palpabil la nivelul arterelor femurale bilateral si diminuat distal bilateral

ECG: ritm sinusal, 75/minut, axa QRS -15, HVS, modificari secundare de repolarizare



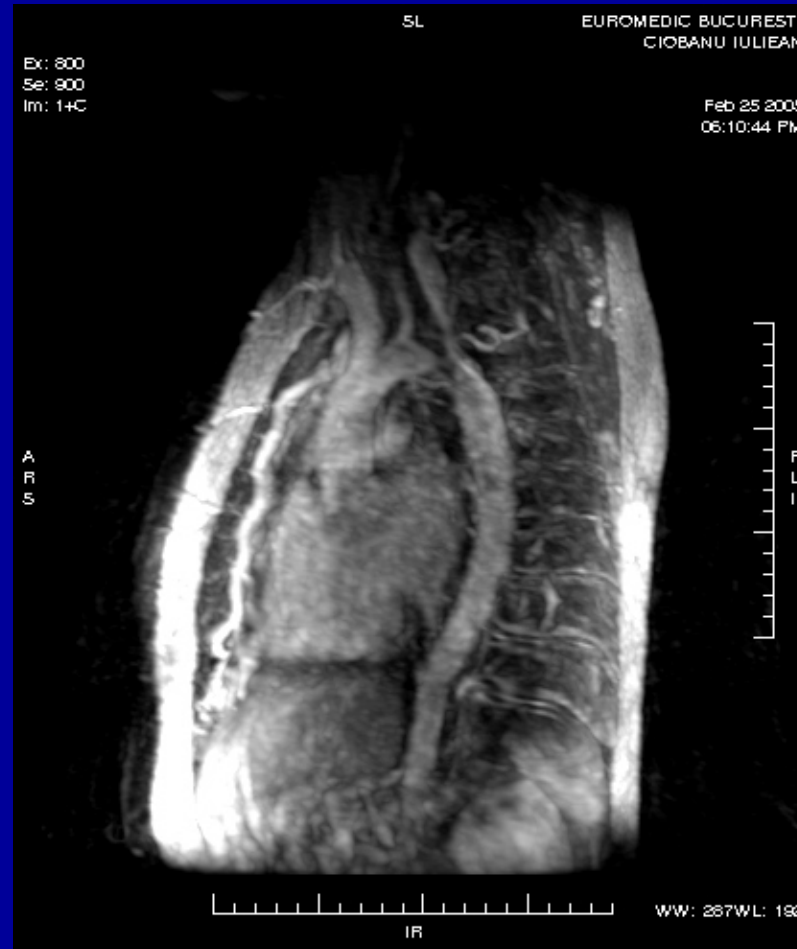Radiografia toracica



Ecocardiografia

- transtoracica: HVS (SIV=19)
Ao inel=19 Ao asc=28 Ao crosa=20
valve aortice tricuspide
- transesofagiana:- pintene fibros ce proemina intraluminal la
nivelul emergentei subclaviei, realizand un
canal circulant de 3-4 mm
-gradient la nivelul aortei descendente 80mmHg

Rezonanta magnetica nucleara

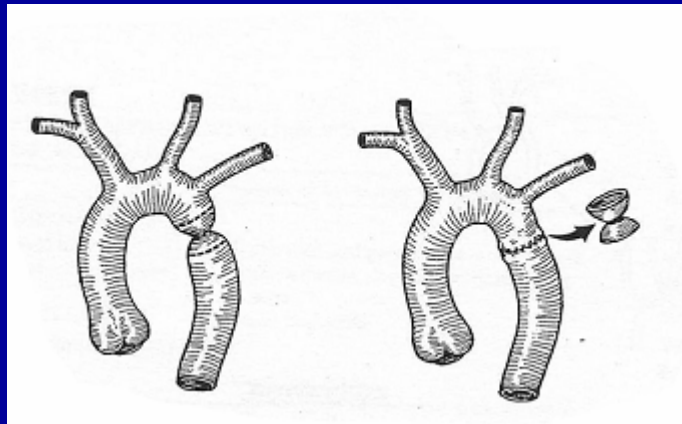


Aortografia

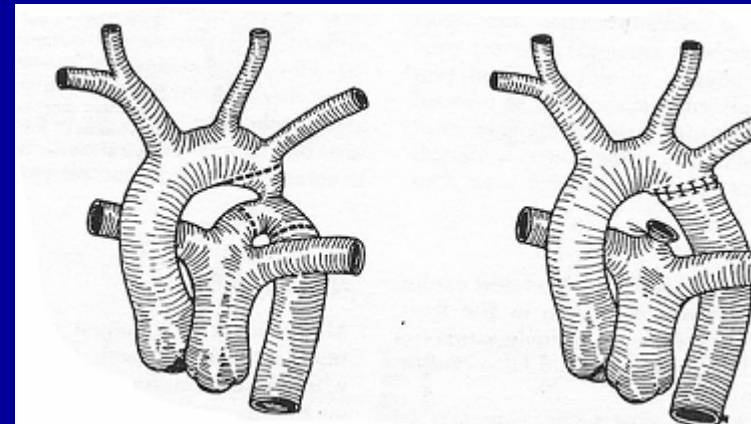


Tratament chirurgical

Rezectie + anastomoza
termino-terminala

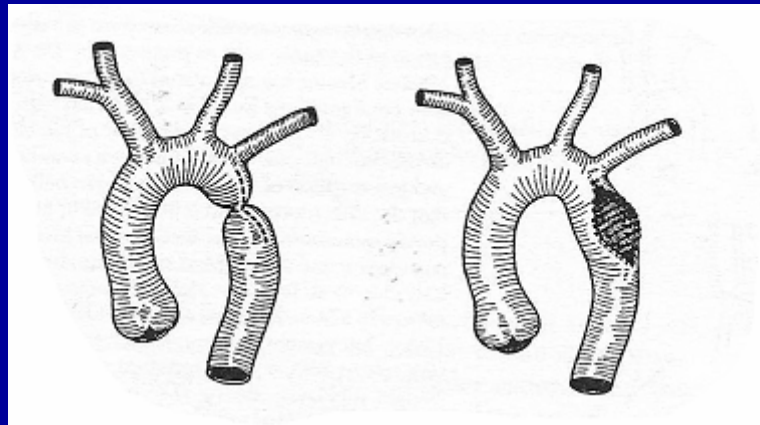


Rezectie + anastomoza
termino-terminala extinsa



Incidenta crescuta a restenozei

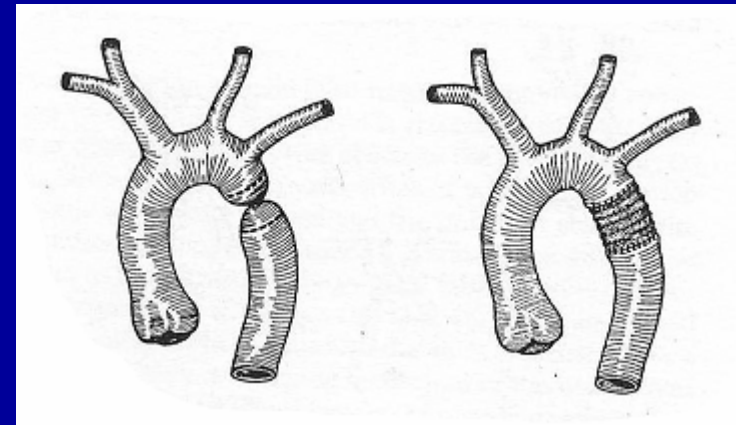
Aortoplastie cu petec de Dacron



Avantaj : incizia redusa a
peretelui aortic

Risc de anevrism

Rezectie + interpozitie de graft prostetic

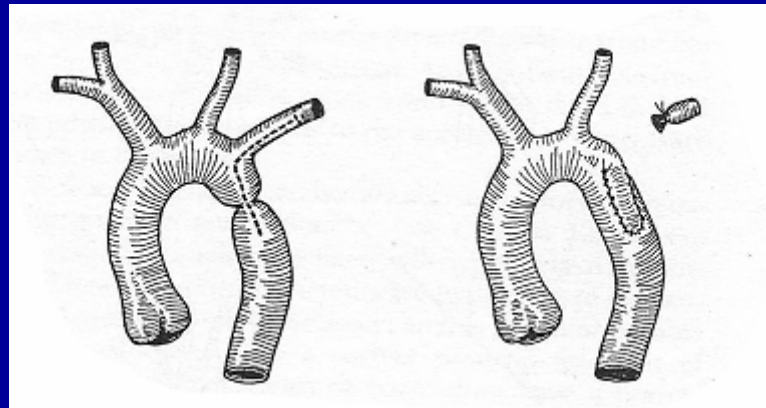


Indicatii:- coarctatie + anevrism
- recoarctatie

Risc de anevrism si infectii

Aortoplastia cu “ flap” artera subclavie

Avantaje: - tehnica operatorie simpla
- timp operator scurt



Dezavantaje: - sacrifica circulatia membrului sup. stang
- anevrism
- recoarctatie

Angioplastia cu balon

- De prima intentie in recoarctatia de aorta
- “ Balloon dilatation has largely been accepted as the treatment of choice for recoarctation of the aorta. “

Stent implantation for aortic coarctation and recoarctation

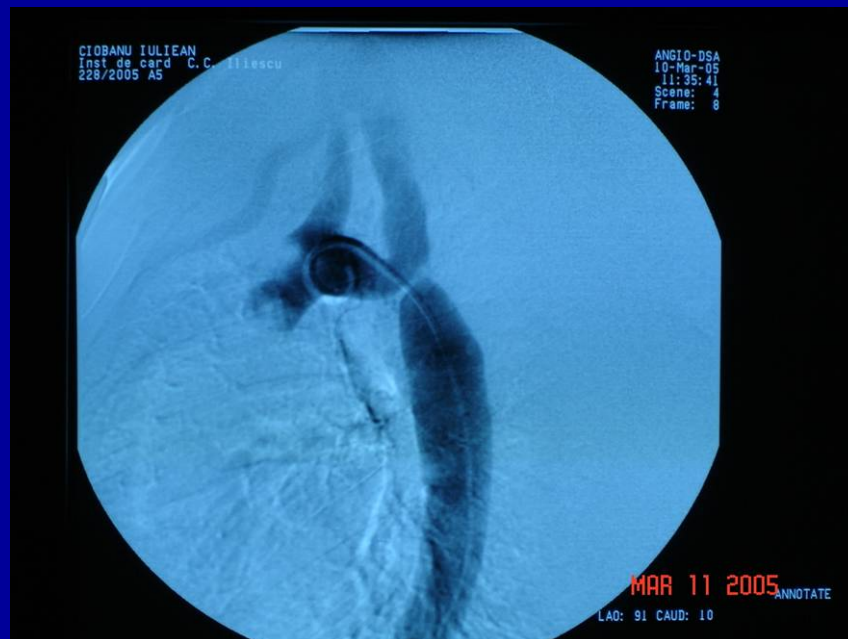
A.G. Magee Heart 1999

Angioplastia cu balon

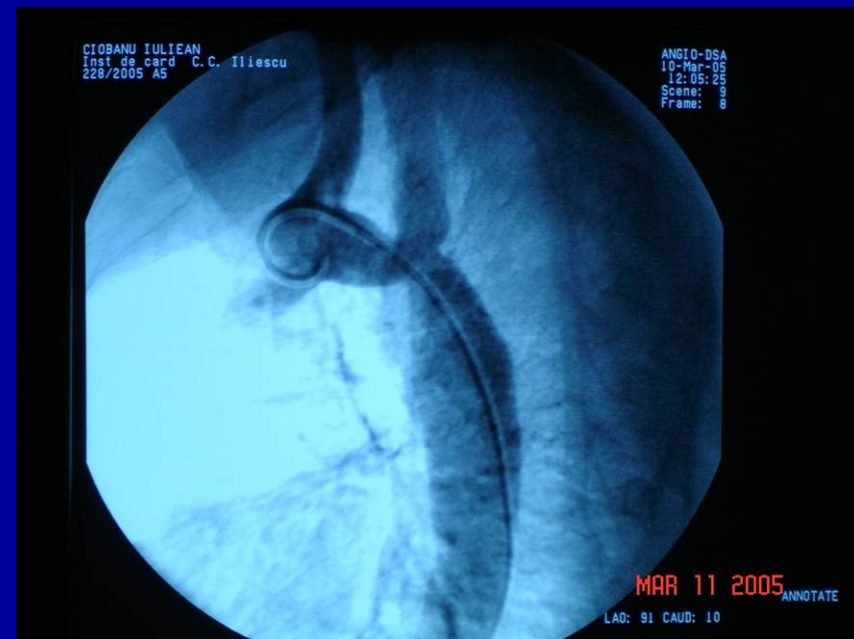
- Rezultate bune 60-75% cazuri
- Complicatii : - gradient rezidual transstenotic ≥ 20 mmHg
in ~ 25 % din cazuri
 - restenozare
 - anevrism
- Implantarea de stent creste eficienta procedurii (reduce gradientul presional transstenotic si riscul de anevrism)

Angioplastie cu balon

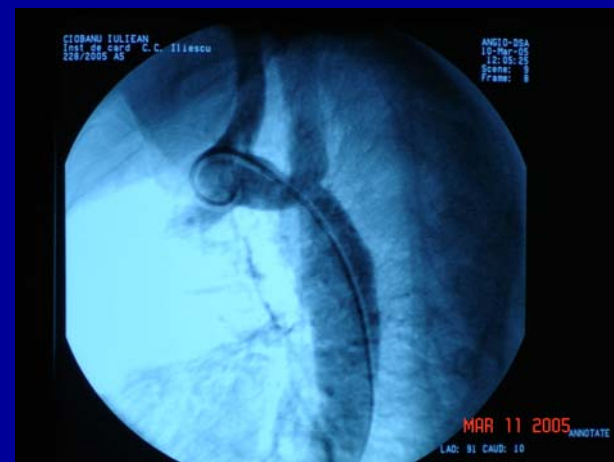
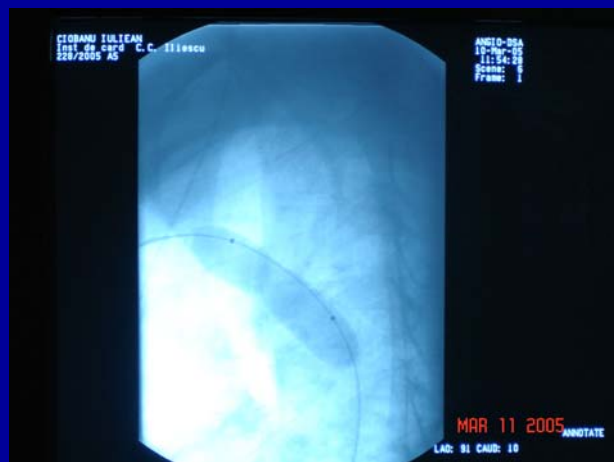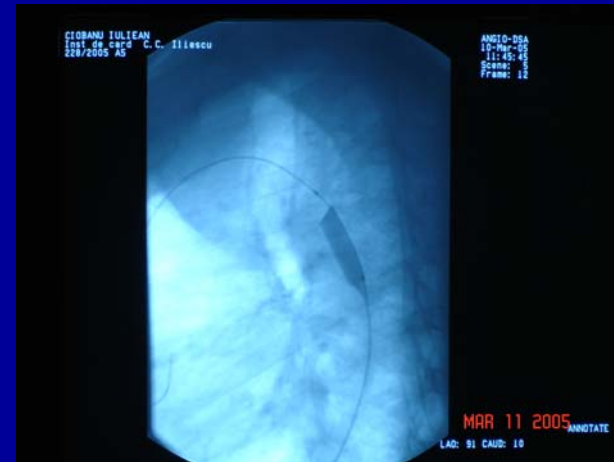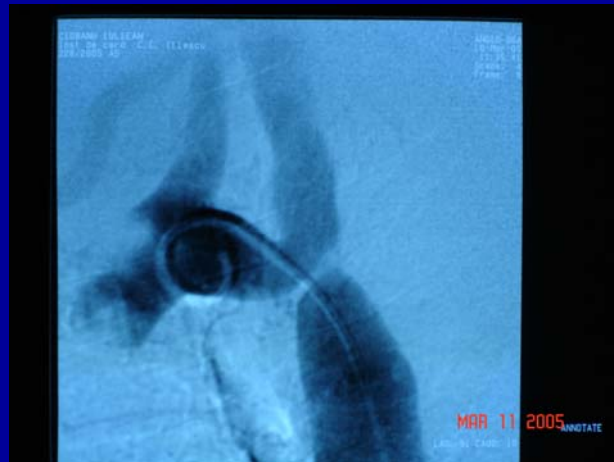Pre-procedura



Post-procedura

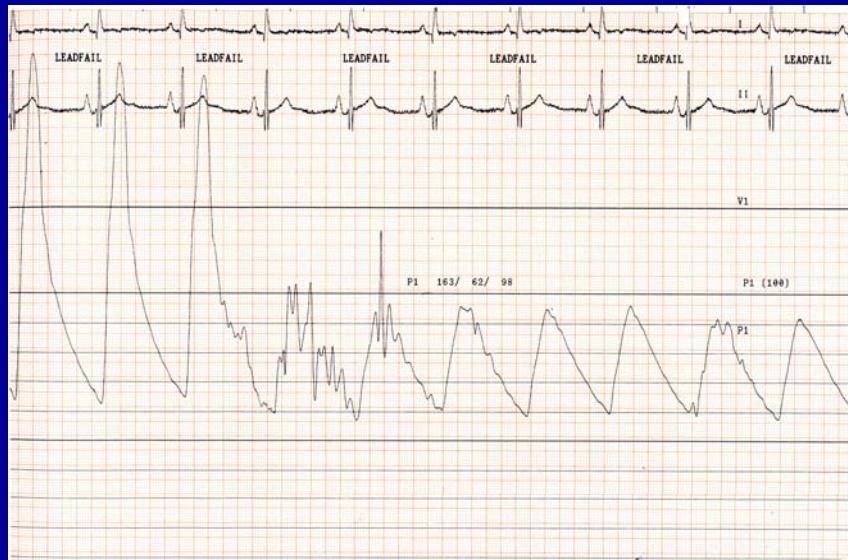


Angioplastie cu balon

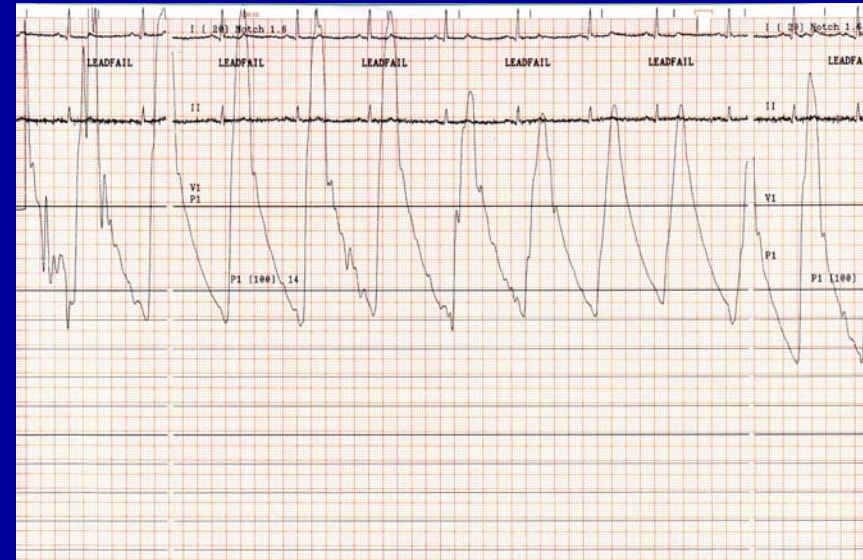


Gradientul sistolic transstenotic


Pre-angioplastie



Post-angioplastie



LA EXTERNARE



TAs=140mmHg

TAs=110mmHg

Claudicatie intermitenta